



# Clinical Practice Procedures: Airway management/Direct laryngoscopy

<b>Policy code</b>	CPP_AM_DL_0221
<b>Date</b>	February, 2021
<b>Purpose</b>	To ensure a consistent procedural approach to direct laryngoscopy.
<b>Scope</b>	Applies to Queensland Ambulance Service (QAS) clinical staff.
<b>Health care setting</b>	Pre-hospital assessment and treatment.
<b>Population</b>	Applies to all ages unless stated otherwise.
<b>Source of funding</b>	Internal – 100%
<b>Author</b>	Clinical Quality & Patient Safety Unit, QAS
<b>Review date</b>	February, 2024
<b>Information security</b>	UNCLASSIFIED – Queensland Government Information Security Classification Framework.
<b>URL</b>	<a href="https://ambulance.qld.gov.au/clinical.html">https://ambulance.qld.gov.au/clinical.html</a>

While the QAS has attempted to contact all copyright owners, this has not always been possible. The QAS would welcome notification from any copyright holder who has been omitted or incorrectly acknowledged.

All feedback and suggestions are welcome. Please forward to: [Clinical.Guidelines@ambulance.qld.gov.au](mailto:Clinical.Guidelines@ambulance.qld.gov.au)

## Disclaimer

The Digital Clinical Practice Manual is expressly intended for use by appropriately qualified QAS clinicians when performing duties and delivering ambulance services for, and on behalf of, the QAS.

The QAS disclaims, to the maximum extent permitted by law, all responsibility and all liability (including without limitation, liability in negligence) for all expenses, losses, damages and costs incurred for any reason associated with the use of this manual, including the materials within or referred to throughout this document being in any way inaccurate, out of context, incomplete or unavailable.

© State of Queensland (Queensland Ambulance Service) 2021.



This work is licensed under the Creative Commons Attribution-NonCommercial-NoDerivatives V4.0 International License

You are free to copy and communicate the work in its current form for non-commercial purposes, as long as you attribute the State of Queensland, Queensland Ambulance Service and comply with the licence terms. If you alter the work, you may not share or distribute the modified work. To view a copy of this license, visit <http://creativecommons.org/licenses/by-nc-nd/4.0/deed.en>

For copyright permissions beyond the scope of this license please contact: [Clinical.Guidelines@ambulance.qld.gov.au](mailto:Clinical.Guidelines@ambulance.qld.gov.au)

# Direct laryngoscopy

February, 2021

**Direct laryngoscopy** is the technique used to achieve optimal visualisation of the glottis for the purpose of oral endotracheal tube insertion or removal of a foreign body.

A laryngoscope consists of a non-disposable handle with a battery powered light source that attaches to a single use fibre optic blade.

Laryngoscopy technique is dependent on the blade selected.

**QAS supplies Laryngoscope blades in two (2) designs:**

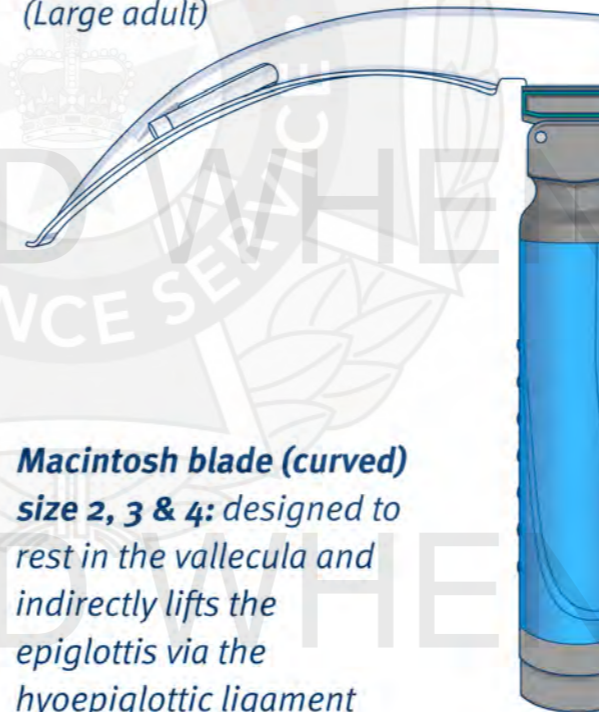
**Macintosh: Size 2**  
(Large child)



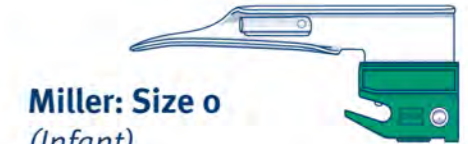**Macintosh: Size 3**  
(Small adult)



**Macintosh: Size 4**  
(Large adult)



**Macintosh blade (curved)**  
**size 2, 3 & 4:** designed to rest in the vallecula and indirectly lifts the epiglottis via the hyoepiglottic ligament to expose the larynx.



**Miller: Size 0**  
(Infant)



**Miller: Size 1**  
(Small child)

**Miller blade (straight)**  
**size 0 & 1:** preferred in infants and young children and designed to lift the epiglottis directly exposing the larynx.

## Indications

- Visualisation of the glottis for the purpose of:
  - oral endotracheal tube insertion
  - removal of a foreign body

## Contraindications

- Suspected or known epiglottitis

## Complications

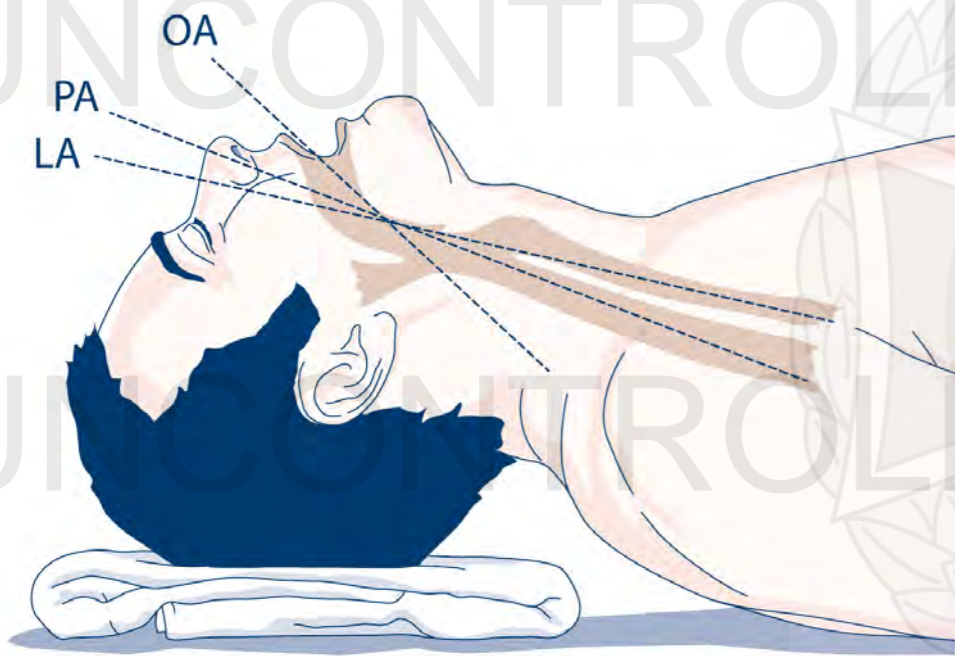
- Laryngospasm
- Hypoxia due to delays in oxygenation while performing the procedure
- Trauma to the mouth or upper airway, particularly teeth/dentures
- Exacerbation of underlying c-spine injuries
- Vomiting/regurgitation



## Procedure – Direct laryngoscopy

### MACINTOSH blade

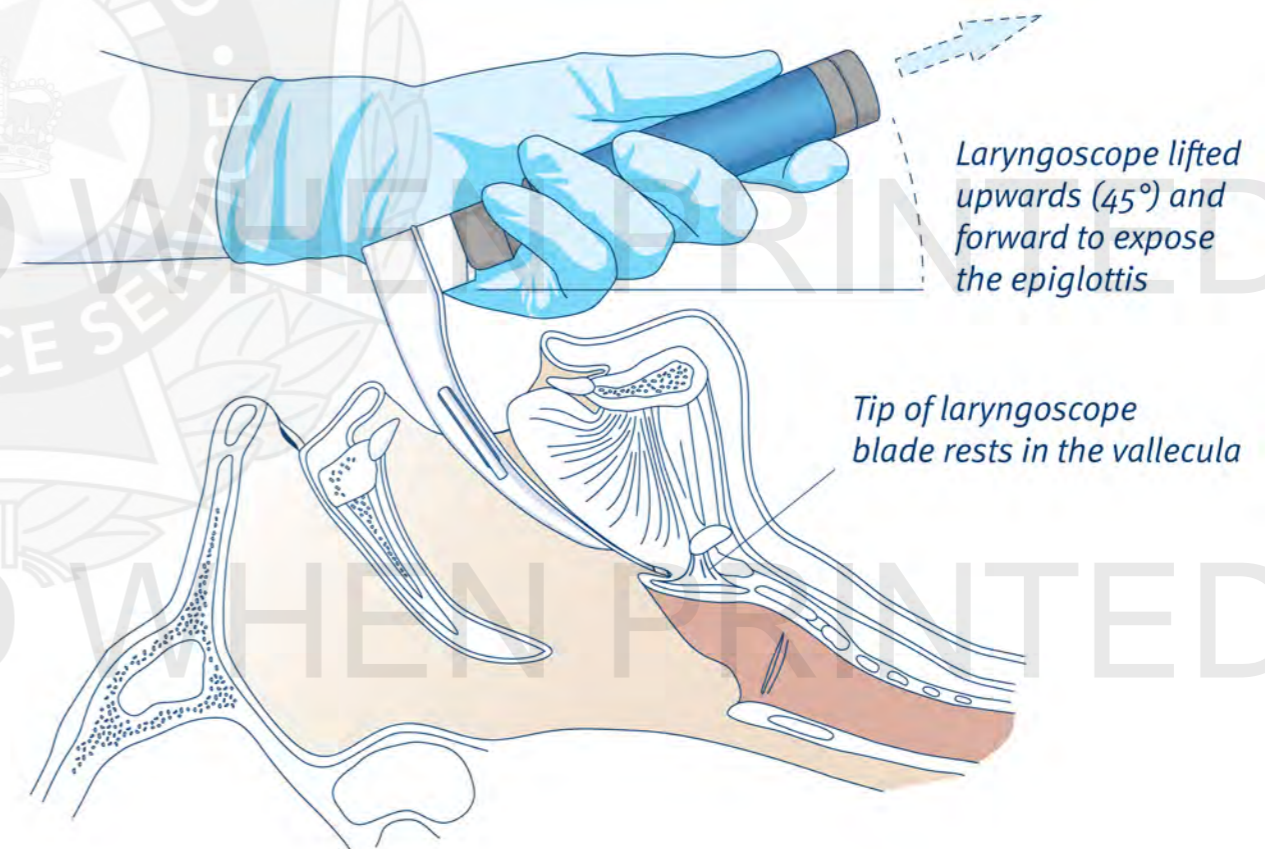
1. Position yourself for optimal visualisation of the larynx.
2. Place the patient's head in the appropriate position to align the oral, pharyngeal and laryngeal axes (neutral position with MILS if c-spine injury suspected).
  - **Infant** – slight elevation of the shoulders
  - **Small child** – slight extension of the head
  - **Older child/adult** – extension of the head (elevation of the head may also be required).



**LEGEND:** oral axis (OA), pharyngeal axis (PA), laryngeal axis (LA)<sup>[1]</sup>

3. Open the patient's mouth and inspect the oral cavity.
4. Remove any dentures or removable plates as required.
5. Grip the laryngoscope handle with the left hand in a position to ensure optimal control and mechanical advantage.

6. Place the laryngoscope blade into the right side of the patient's mouth, gently sweep the tongue to the left and position the blade midline in the mouth.
7. If laryngoscope blade is difficult to position correctly<sup>[2]</sup>, consider:
  - inserting the blade separately and reconnecting with the handle when in position; or
  - inserting the laryngoscope blade while the handle is angled and once in the oral cavity, rotate the laryngoscope to the midline
8. Move the laryngoscope blade progressively down the tongue identifying relevant anatomy.
9. Gently place the tip of the laryngoscope blade in the vallecula.
10. Lift the blade upwards and forward at a 45° angle to expose the epiglottis.

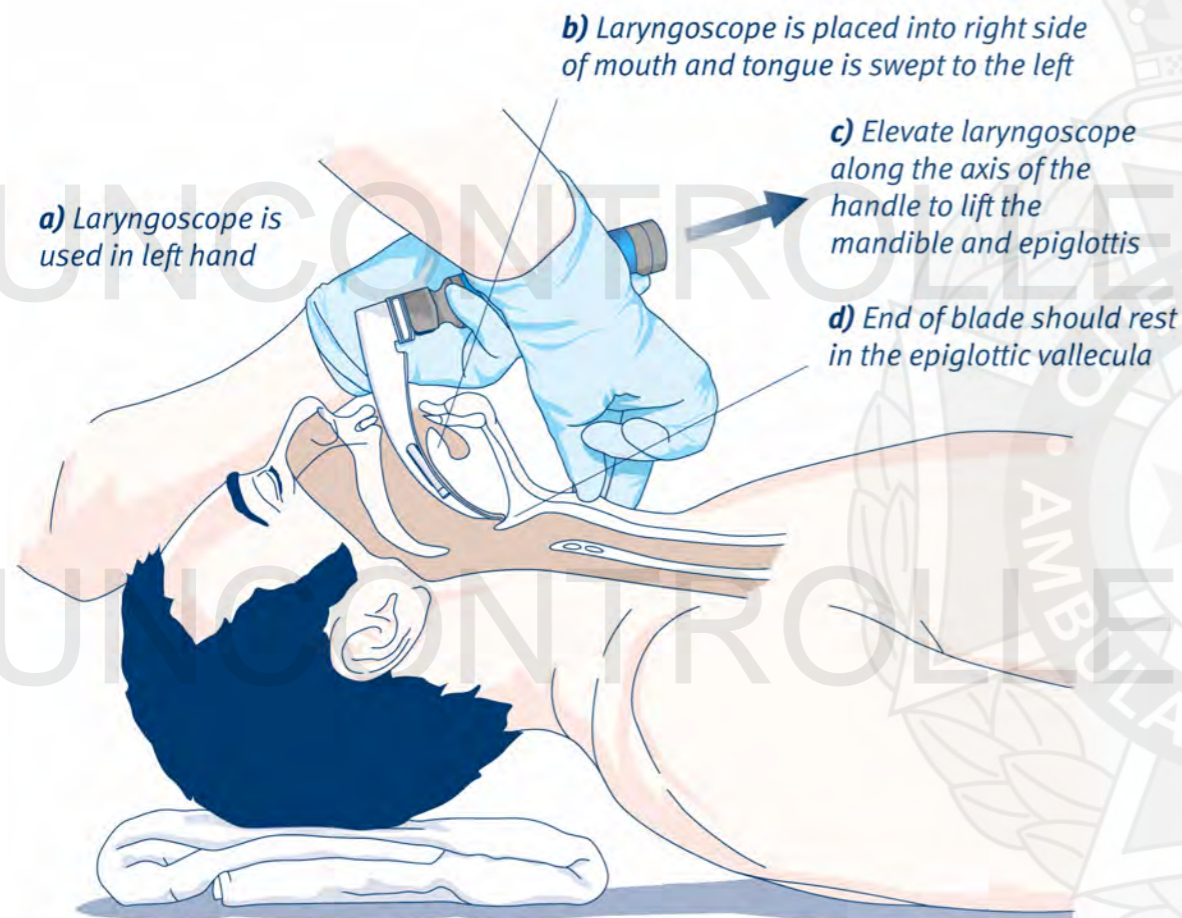




## Procedure – Direct laryngoscopy

### MACINTOSH blade (cont.)

11. Identify glottic structures (commences with the posterior cartilages and interarytenoid notch, before the glottic opening and the vocal cords come into view). If view of the glottic structures is poor, consider suctioning and/or external laryngeal manipulation (refer to *CPP: Laryngeal manipulation*).



### MILLER blade

1. Position yourself for optimal visualisation of the larynx.
2. Place the patient's head in the sniffing position to align the oral, pharyngeal and laryngeal axes (neutral position with MILS if c-spine injury suspected).



3. Open the patient's mouth and inspect the oral cavity.
4. Grip the laryngoscope handle with the left hand in a position to ensure optimal control and mechanical advantage.
5. Place the laryngoscope blade into the right side of the patient's mouth, gently sweep the tongue to the left and position the blade midline in the mouth.
6. As the laryngoscope blade tip approaches the base of the tongue, perform one (1) of the two (2) following techniques:
  - Insert the laryngoscope blade tip under and slightly beyond the epiglottis; or
  - Gently advance the laryngoscope blade further down the tongue until the epiglottis has been identified.
7. Lift the epiglottis and gently withdraw the blade to allow the laryngeal inlet to drop into view (the lack of identifiable structures indicates oesophageal passage).
8. Identify glottic structures (commences with the posterior cartilages and interarytenoid notch, before the glottic opening and the vocal cords come into view). If view of the glottic structures is poor, consider suctioning and/or laryngeal manipulation.

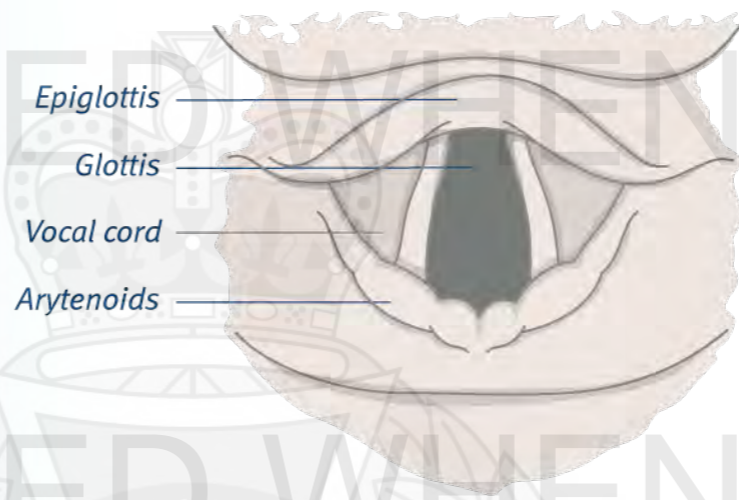
## Additional information

- Airways should be graded using the Cormack-Lehane classification. The grade is allocated according to the best airway view achieved.

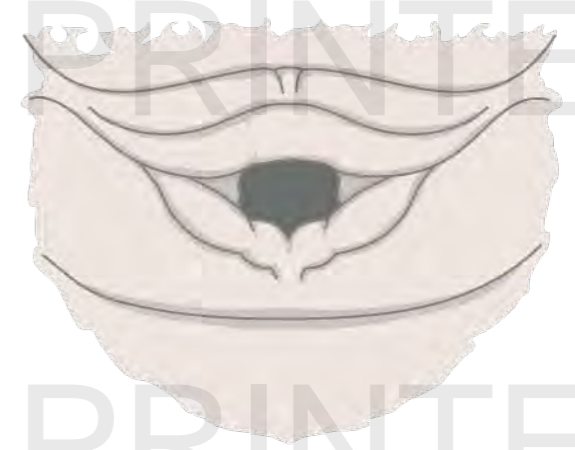Cormack-Lehane Classification	
<b>Grade I</b>	Complete glottis visible
<b>Grade II</b>	Anterior glottis not seen
<b>Grade III</b>	Epiglottis seen, but not glottis
<b>Grade IV</b>	Epiglottis not seen

### NUMBER OF ATTEMPTS

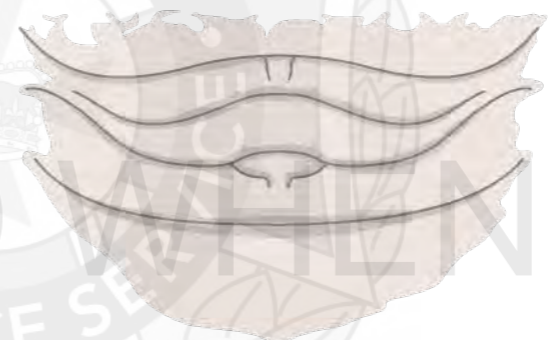- This procedure is limited to **two** attempts per officer.



**Grade I**



**Grade II**



**Grade III**



**Grade IV**